

NSL 02617

REM SLEEP SIGNS ROSTRAL TO CHRONIC TRANSECTIONS AT THE PONTOMEDULLARY JUNCTION

J.M. SIEGEL, R. NIENHUIS and K.S. TOMASZEWSKI

Neurobiology Research, V.A. Medical Center, Sepulveda, CA 91343 and Department of Psychiatry, UCLA School of Medicine, Los Angeles, CA 90024 (U.S.A.)

(Received September 13th, 1983; Revised version received and accepted December 20th, 1983) *Key*

words: REM sleep - transection - brainstem - pons - medulla - cats

The brainstems of 3 cats were transected at the ponto-medullary junction and the cats maintained in stable condition for periods of from 16 to 31 days. After transection, all of these cats had periods in which forebrain sensorimotor cortex, olfactory bulb, hippocampus, eye movement and lateral geniculate recordings exhibited the pattern of activity seen only in REM sleep in the intact cat. We conclude that medullary regions are not required to generate these signs of REM sleep. The pons is necessary for REM sleep and is sufficient to produce REM sleep signs in rostral as well as caudal brain regions. However, the medulla may contribute to regulation of the duration and periodicity of REM sleep.

Transection studies have clearly established that structures rostral to the midbrain are not required to generate the brainstem signs of REM sleep [3, 5, 14]. Similarly, transections at the spino-medullary junction have established that structures in the spinal cord are not required for REM sleep [1, 9]. Therefore, it is clear that the ponto-medullary brainstem contains the brain regions critical for REM sleep generation. Further experimental localization of the areas required for REM sleep generation has relied largely on experiments in which portions of the brainstem were destroyed in order to disrupt REM sleep [2, 4, 6, 10]. Interpretation of such studies is always difficult, since the loss of REM sleep may be due to non-specific factors. This is especially true in medullary regions, where lesions often cause the death of the animal. Therefore the medullary role in REM sleep control is largely unknown.

Further progress in the localization of REM sleep control mechanisms could be achieved if it were possible to demonstrate, with positive evidence, that a more restricted region of the ponto-medullary brainstem was sufficient to generate REM sleep signs. In the present study we have transected the brainstem at the ponto-medullary junction. The medullary portion of these animals did not have any of the local signs of REM sleep [13]. We now report that the forebrain and attached pons of this preparation do have REM sleep signs. Therefore the pontine brainstem is sufficient to produce REM sleep signs in rostral as well as caudal brain regions.

Cats were implanted with screw electrodes for recording sensorimotor elec-

troencephalograph (EEG) and electrooculogram (EOG). Moveable drives containing macroelectrodes aimed at the dorsal hippocampus and at the lateral geniculate nucleus (LGN) were implanted [11]. After a minimum of one week, the drives were adjusted to produce optimal recordings of LGN ponto-geniculo-occipital (PGO) spikes and hippocampal theta. At least 8 continuous hours of baseline recordings were then made. After a minimum of two weeks the transection surgery was performed. Halothane/oxygen anesthesia was employed. The medial cerebellum was aspirated to expose the aqueduct and rostral portion of the floor of the fourth ventricle. A spatula was then lowered to transect the brainstem. After controlling bleeding with bovine thrombin, the skull opening was sealed with dental cement. The cat was then removed from the stereotaxic and placed on a heating pad in the recording chamber where polygraphic variables were recorded throughout the survival period.

Expired CO₂ levels were maintained, without assistance, in the 4-5.5% range in all cats with the exception of cat 46. Cat 46, after maintaining his expired CO₂ level in the normal range for 7 days, became hypercapnic and was placed on a respirator for 2 days. After this period he was again able to regulate CO₂ level without assistance.

The output of a rectal thermometer controlled a water circulating heating pad, maintaining core temperature between 37 and 38.5°C. Nutrition was provided by administration of 5% dextrose and amino acid solution (Freamine, McGaw) subcutaneously or liquid food (KMR, Borden Inc.) by gavage.

Cats were maintained in stable condition for 16-31 days and then killed with an overdose of Nembutal. After perfusing with saline and 10% formalin, brains were removed and sectioned in the sagittal plane.

Three cats were transected at the ponto-medullary junction. Dorsally the transections passed between the rostral and caudal portions of the abducens nucleus, inclined at 30° off vertical. Ventrally they passed through the trapezoid body caudal to the basilar pons (Fig. 1). The transections were quite complete, with a few filaments of the trapezoid body spared in one cat. Results in this cat did not differ from the two with complete transections.

By post-transection day two, a state with EEG and olfactory bulb desynchrony, PGO spikes and PGO spike bursts and hippocampal theta was observed in all 3 cats. This state closely resembled the REM sleep state seen during baseline recordings (Fig. 2) and recurred throughout the survival period. Rapid eye movements were concentrated in this state but could also be seen in other states. States similar to waking and non-REM sleep were also observed.

Parameters of the REM sleep-like state were calculated for day 7 (Table I). The cycle length for the REM-like state was significantly shorter after transection than in the baseline period ($P < 0.03$ 2-tailed t -test). Mean state duration was not significantly different after transection (t -test). However state durations were more variable after transection with the standard deviation of state duration being

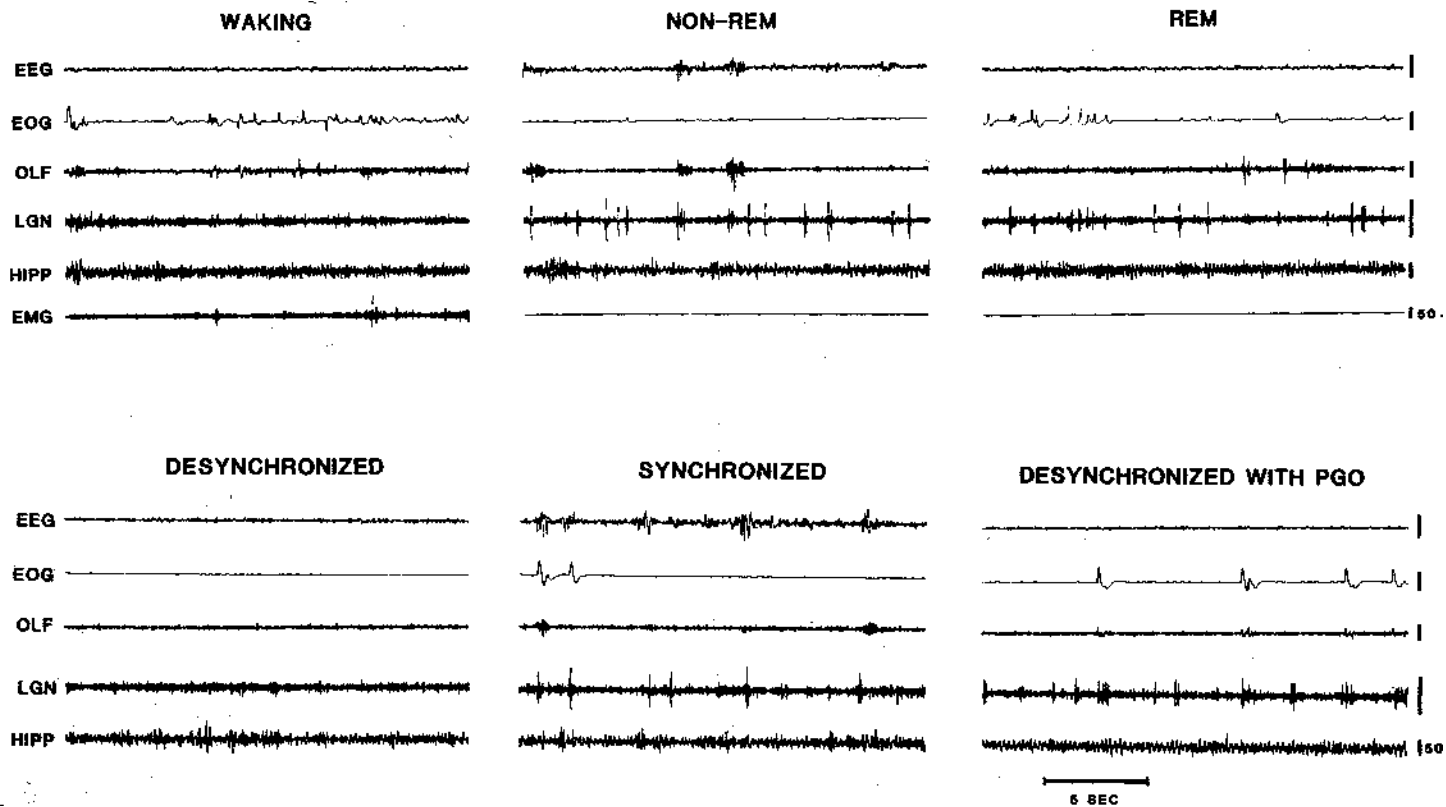


Fig. 2. Behavioral States seen in the intact cat (top) compared to states on fourth post-transection day (bottom) in same cat (#80). EEG, sensorimotor electroencephalogram; EOG, electrooculogram; OLF, olfactory bulb; LGN, lateral geniculate nucleus; HIPP, hippocampus; EMG, dorsal neck electro-myogram

significantly greater ($P < 0.02$, 2-tailed t -test). All transected cats showed some REM sleep-like states with durations exceeding 25 min, far longer than any REM sleep state seen in intact cats.

We find all of the constellation of forebrain signs used to identify the REM sleep state in the intact cat, including PGO spike bursts, rapid eye movements, olfactory bulb and EEG desynchrony, and hippocampal theta, present in the forebrain-pons

of the chronic transected medullary cat. It remains possible that some critical feature of REM sleep may be identified that would distinguish it from the state we observe in these transected animals. However it seems reasonable to identify this state as a REM sleep-like state. The medulla is not required to generate this pattern of activity. However, the pons and attached forebrain are sufficient to generate these signs.

A previous study by Jouvet attempted a positive localization of REM sleep control mechanisms using transections through the mid and caudal pons [5]. Three states were identified in the rostral portion of these preparations: waking, non-REM sleep and 'a difficult to interpret' state. This latter condition was suspected of being a REM sleep state. However because only cortical EEG was recorded it was not possible to conclusively identify this state as REM sleep and thereby definitively localize REM sleep control mechanisms to the mid and rostral pons. Also, the short survival times may not have allowed the full emergence of all behavioral states. In an earlier study we performed a similar series of transections just caudal to the locus coeruleus, maintaining the cats for as long as 30 days and recording reticular unit activity and PGO spikes. We found that the rostral portion of these preparations did not have REM sleep signs [12]. PGO spikes were seen only in conjunction with EEG synchrony. It therefore appears that the most caudal portions of the pons, which are rostral to the level of transection in the present study, are critical for the generation of this state. Included in this region is the caudal portion of the pontine central gray, the lateral tegmental field and the caudal peribrachial region. Acute studies [7, 8] have demonstrated that rostral pontine mechanisms are sufficient to generate PGO spikes. This is consistent with our observation of PGO spikes, in the absence of other REM sleep signs, after our rostral transections.

While a REM sleep-like state was present in cats transected at the ponto-medullary junction, the timing of this state was quite different from that seen in the intact cat. Specifically the duration of this state was often far greater than the maximum durations seen in intact cats and the intervals between episodes were shorter than those seen in intact cats. Thus the medullary brainstem may play a critical role in regulating the timing of the REM sleep state.

Supported by the Medical Research Service of the Veterans Administration, PHS Grant NS14610 and NSF Grant BNS00023.

- 1 Adey, W.R., Bors, E. and Porter, R.W., EEG sleep patterns after high cervical lesions in man, *Arch. Neurol.*, 19 (1968) 377-383.
- 2 Carli, G. and Zanchetti, A., A study of pontine lesions suppressing deep sleep in the cat, *Arch. ital. Biol.*, 103 (1965) 751-788.
- 3 Hobson, J. A., The effects of chronic brain-stem lesions on cortical and muscular activity during sleep and waking in the cat, *Electroenceph. clin. Neurophysiol.*, 19 (1965) 41-62.
- 4 Jones, B.E., Harper, S.T. and Halaris, A.E., Effects of locus coeruleus lesions upon cerebral monoamine content, sleep wakefulness states and the response to amphetamine in the cat, *Brain Res.*, 124 (1977) 473-496.
- 5 Jouvet, M., Recherches sur les structures nerveuses et les mecanismes responsables des differentes phases du sommeil physiologique, *Arch. ital. Biol.*, 100 (1962) 125-206.
- 6 Jouvet, M. and Delorme, F., Locus coeruleus et sommeil paradoxal, *C.R. Soc. Biol.*, 159 (1965) 895-899.
- 7 Laurent, J.P., Cespuglio, R. and Jouvet, M., Delimitation des voies ascendants de l'activite ponto-geniculo-occipitale chez le chat, *Brain Res.*, 65 (1974) 29-52.
- 8 Matsuzaki, M., Differential effects of sodium butyrate and physostigmine upon the activities of para-sleep in acute brain stem preparations, *Brain Res.*, 13 (1969) 247-265.
- 9 Puizillout, J.J., Ternaux, J.P., Foutz, A.S. and Fernandez, G., Les stades de sommeil de la preparation 'encephale isole'. I. Declenchement des pointes ponto-geniculo-occipitales et du sommeil phasi-que a ondes lentes. Role des noyaux du raphe, *Electroenceph. clin. Neurophysiol.*, 37 (1974) 561-576.
- 10 Sastre, J.P., Sakai, K. and Jouvet, M., Persistence du sommeil paradoxal chez le chat apres destruction de l'aire gigantocellulaire du tegmentum pontique par l'acid kainique, *C.R. Acad. Sci.*, 289D (1979) 959-964.
- 11 Siegel, J.M., McGinty, D.J. and Breedlove, S.M., Sleep and waking activity of pontine gigantocellular field neurons, *Exp. Neurol.*, 56 (1977) 553-573.
- 12 Siegel, J.M., Nienhuis, R., Tomaszewski, K.S. and Wheeler, R., Behavioral states after brainstem transection at the medullary level, *Soc. Neurosci. Abstr.*, 7 (1981) 233.
- 13 Siegel, J.M., Tomaszewski, K.S. and Nienhuis, R., Behavioral states in the chronic medullary and midpontine cat, submitted.
- 14 Villablanca, J., Behavioral and polygraphic study of 'sleep' and 'wakefulness' in chronic decerebrate cats, *Electroenceph. clin. Neurophysiol.*, 21 (1966) 562-577.