

Narp immunostaining of human hypocretin (orexin) neurons

Loss in narcolepsy

A.M. Blouin, BS; T.C. Thannickal, PhD; P.F. Worley, MD; J.M. Baraban, MD, PhD; I.M. Reti, MD; and J.M. Siegel, PhD

Abstract—Objective: To investigate whether neuronal activity-regulated pentraxin (Narp) colocalizes with hypocretin (Hcrt or orexin) in the normal human brain and to determine if Narp staining is lost in the narcoleptic human brain. **Background:** Human narcolepsy is characterized by a loss of the peptide hypocretin in the hypothalamus. This loss could result from the degeneration of neurons containing hypocretin or from a more specific loss of the ability of these neurons to synthesize Hcrt. Narp has been found to colocalize with hypocretin in the rat hypothalamus. **Methods:** We investigated the distribution of Narp in three normal and four narcoleptic human postmortem brains using immunohistochemistry with an antibody to Narp. Colocalization studies of Narp and hypocretin were also performed in two normal brains using immunohistochemistry with an antibody to Narp and an antibody to hypocretin. **Results:** We found that Narp colocalizes with hypocretin in the lateral hypothalamic area (LHA), the dorsomedial hypothalamus (DMH), the dorsal hypothalamic area (DHA), and the posterior hypothalamic area (PHA) of the normal human. The number of Narp-positive neurons was reduced by 89% in these areas of the narcoleptic hypothalamus. In contrast, Narp staining in the paraventricular (Pa) and supraoptic nuclei (SO) of the human hypothalamus did not differ between normal and narcoleptic brains. **Conclusions:** This finding supports the hypothesis that narcolepsy results from the specific loss of hypocretin neurons. Loss of hypothalamic Narp may contribute to the symptoms of narcolepsy.

NEUROLOGY 2005;65:●●●-●●●

Narcolepsy affects more than one in 2,000 individuals. It is characterized by excessive daytime sleepiness and sleep attacks, but often involves other irregularities of the sleep-wake cycle as well as episodic loss of muscle tone (cataplexy). Our lab showed that human narcoleptics have an 85% to 95% loss of neurons staining for the neuropeptide hypocretin (Hcrt, also known as orexin) in the hypothalamus, and others were unable to detect Hcrt in the brains of human narcoleptics.^{1,2} It is not known whether the loss of Hcrt staining in the hypothalamus results

from a failure of hypocretin synthesis or from the death of the hypocretin synthesizing neurons.

Hypocretin neurons in the lateral hypothalamic area of the human express prodynorphin mRNA.³ Another molecule found to colocalize with hypocretin in the rat brain is neuronal activity-regulated pentraxin (Narp), a 46-kDa secreted immediate early gene product. In the rat hypothalamus, more than 99% of all hypocretin neurons express Narp and more than 99% of Narp neurons are hypocretin-positive.⁴ Narp has also been found in other regions of the rat brain including the paraventricular and supraoptic nuclei of the hypothalamus (unpublished data).

In this study, we investigated Narp in normal and

Additional material related to this article can be found on the *Neurology* Web site. Go to www.neurology.org and scroll down the Table of Contents for the October 25 issue to find the title link for this article.

Editorial, see page ●●●
See also page ●●●

This article was previously published in electronic format as an Expedited E-Pub.

From the Department of Psychiatry and Brain Research Institute (A.M. Blouin, Dr. Thannickal, and Dr. Siegel), University of California, Los Angeles, CA; the Neurobiology Research (A.M. Blouin, Dr. Thannickal, and Dr. Siegel), VA Greater Los Angeles Healthcare System, North Hills, CA; and the Departments of Neuroscience (Drs. Worley and Baraban), Neurology (Dr. Worley), and Psychiatry and Behavioral Sciences (Dr. Baraban and Reti), Johns Hopkins University School of Medicine, Baltimore, MD.

Supported by NIH grants NS14610, MH64109, HL41370, the Medical Research Service of the Department of Veterans Affairs, and the Howard Hughes Medical Institute Predoctoral Fellowship (A.B.).

Disclosure: The authors report no conflicts of interest.

Submitted in preliminary form on May 19, 2004 for presentation at the Society for Neuroscience Meeting.

Presented at the Society for Neuroscience Meeting, San Diego, CA, October 24, 2004.

Received December 23, 2004. Accepted in final form June 2, 2005.

Please address correspondence and reprint requests to Dr. J.M. Siegel, Neurobiology Research 151A3, VA Greater Los Angeles Healthcare System, 16111 Plummer Street, North Hills, CA 91343; e-mail: jsiegel@ucla.edu.

narcoleptic human hypothalami. Specifically, we sought to determine whether Narp colocalizes with hypocretin in the lateral hypothalamic area (LHA), the dorsomedial hypothalamus (DMH), the dorsal hypothalamic area (DHA), and the posterior hypothalamic area (PHA). We also quantified Narp staining in these nuclei as well as in the paraventricular (Pa) and supraoptic nuclei (SO) of both normal and narcoleptic hypothalami to determine if there is a generalized loss of Narp neurons in narcolepsy and if the loss of hypocretin staining is accompanied by a comparable loss of Narp-positive neurons.

Methods. Four narcoleptic (N1–N4) and three neurologically normal brains (C1–C3) were used in this study (see table E-1 on the *Neurology* Web site at www.neurology.org). Narcolepsy was diagnosed according to standard criteria.⁵

Immunohistochemistry. Brains were fixed in 10% formalin and sectioned into 40- μ m thick coronal sections. For all immunostaining, narcoleptic and control tissue were stained in pairs and no primary antibody controls were included. All three of the normal brains and two of the four narcoleptic brains had been used previously in studies assessing hypocretin cell loss.¹ To confirm hypocretin loss in the remaining brains, antigen retrieval and immunostaining for hypocretin was performed.¹ Antibodies used were orexin-A primary antibody (72 hours, 1:2,000; Oncogene Research Products, Boston, MA) and a biotinylated goat antirabbit secondary antibody (2 hours, 1:500; Vector Laboratories, Burlingame, CA). Staining was visualized using avidin-biotin peroxidase (1:300, ABC Elite Kit; Vector Laboratories) and diaminobenzidine (1 drop/10 mL, DAB; Vector Laboratories).

Narp antigen retrieval and immunostaining were performed as described⁶ except sections were incubated in Triton X-100 for 30 minutes prior to mounting. A rabbit polyclonal Narp primary antibody (72 hours, 1:3,000) and a biotinylated goat antirabbit secondary antibody (20 hours, 1:200) were used. Staining was visualized using ABC solution (1:50) followed by incubation in DAB (1:25).

For hypocretin and Narp colocalization studies, antigen retrieval was performed as reported for Narp immunostaining (see above) except that sections were boiled for only 10 minutes. Primary antibodies were goat polyclonal hypocretin-1 (72 hours, 1:500, Santa Cruz Biotechnology, Santa Cruz, CA) and the Narp antibody (72 hours, 1:750) described above. Secondary antibodies were Alexa Fluor 488-conjugated donkey antigoat (20 hours, 1:500, Molecular Probes, Eugene, OR) and Cy3 conjugated donkey antirabbit (20 hours, 1:500, Jackson ImmunoResearch Laboratories, West Grove, PA).

Data analysis. For quantification of Narp staining, one anterior hypothalamic section, one middle hypothalamic section, and one posterior hypothalamic section were analyzed from each brain when tissue was available. The following brain tissue was unavailable: anterior hypothalamic tissue from N2, middle hypothalamic tissue from N4, and posterior hypothalamic tissue from C2, N3, and N4. Thus, for quantification in the anterior hypothalamus, one section from C1, C2, C3, N1, N3, and N4 was used. For quantification of staining in middle hypothalamus, one section from C1, C2, C3, N1, N2, and N3 was used. For quantification in posterior hypothalamus, one section from C1, C3, N1 and N2 was used. Each narcoleptic section was matched to a control section. Matches were made according to the position of the fornix or mammillo-tegmental tract. Section levels were defined using the *Atlas of the Human Brain*⁷ as follows: anterior hypothalamic sections (levels 24–26), middle hypothalamic sections (levels 27–29), and posterior hypothalamic sections (level 31). Within the anterior hypothalamic level, the following nuclei were analyzed: Pa, SO, and LHA. Within the middle hypothalamic level, the following nuclei were analyzed: LHA, DMH, and DHA. Within the posterior hypothalamic level, the following nuclei were analyzed: LHA and PHA.

DAB-stained cells were counted using NeuroLucida software. For statistical analysis, paired Student's *t*-test was used. For computing the overall percent decrease in Narp staining, the percent

decrease was calculated for each individual nucleus and then all nuclei were averaged together.

Results. *Narp and hypocretin colocalization.* Sections from normal brains C1 and C2 were used for the colocalization studies. In both brains, Narp and hypocretin were found to colocalize in the LHA, DMH, DHA, and PHA (see figure E-1 on the *Neurology* Web site at www.neurology.org). In these areas, nearly all hypocretin cells (>99%) stained positive for Narp and nearly all Narp cells (>99%) stained positive for hypocretin. For the most part, Narp and hypocretin were colocalized in the hypothalamic ax-

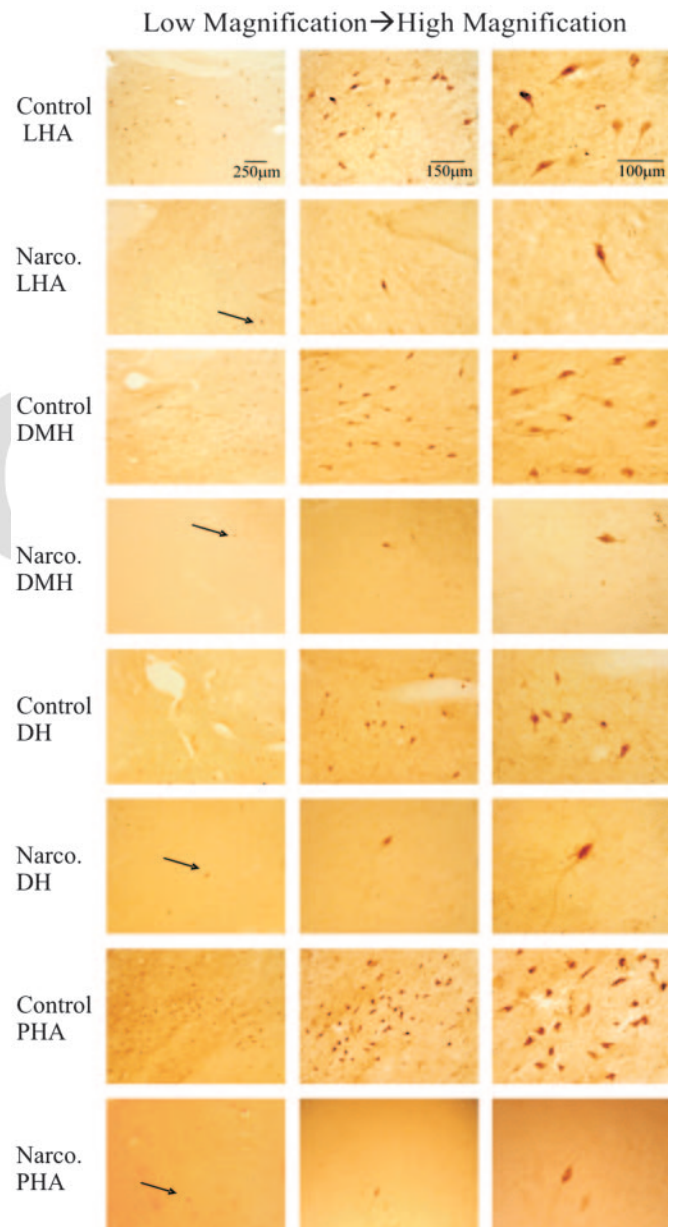


Figure 1. Narp staining with DAB in the LHA, DMH, DHA, and PHA of narcoleptic and control tissue. Left column shows low-power images of matched normal and narcoleptic LHA, DMH, DHA, and PHA. Middle and right columns show increasingly higher power images of the same area shown in the left column. Scale bars in each column apply to all panels below and within the same column.

Table The number of Narp-positive neurons in the LHA, DMH, DHA, PHA, SO and Pa in narcoleptic and control sections

Section Location, brain area/level	Number of Narp-positive cells	
	Control	Narcoleptic
LHA/Anterior	82	12
LHA/Anterior	147	9
LHA/Anterior	112	8
LHA/Middle	135	16
LHA/Middle	133	11
LHA/Middle	198	14
LHA/Posterior	67	3
LHA/Posterior	105	15
DHA/Middle	69	13
DHA/Middle	43	8
DHA/Middle	54	5
DMH/Middle	123	3
DMH/Middle	146	10
DMH/Middle	208	14
PHA/Posterior	96	14
PHA/Posterior	40	6
Pa/Anterior	54	45
Pa/Anterior	151	105
Pa/Anterior	92	71
SO/Anterior	107	123
SO/Anterior	77	91
SO/Anterior	33	51

Matched sections are listed across from each other and matches are listed vertically from most anterior to most posterior.

ons, although axons staining only for Narp or only for hypocretin were observed.

Narp staining and analysis. The number of Narp-positive neurons was reduced in the LHA, DMH, DHA, and PHA of the narcoleptic sections compared to control tissue (figure 1, table; $p < 0.001$, $df = 15$). Overall, the number of Narp-positive neurons in the LHA, DMH, DHA, and PHA combined was decreased by 89% in the narcoleptic tissue. On the other hand, the number of Narp-positive neurons in the SO and Pa of the narcoleptic sections was not different from the number of Narp-positive neurons in the Pa and SO of the control tissue (figure 2, see table; $p = 0.674$, $df = 5$). The anterior hypothalamic Pa and SO regions analyzed in this study do not contain hypocretin cells.

Discussion. We have previously found that, in the narcoleptic hypothalamus, hypocretin staining is decreased by 85% to 95%. Due to the presence of gliosis, we attributed this decrease to loss of the actual neurons by an inflammatory process rather than specific loss of the peptide hypocretin.^{1,8} We now show further evidence that the loss in narcolepsy represents more than just the absence of the peptide hypocretin. We find that hypocretin cells in the LHA,

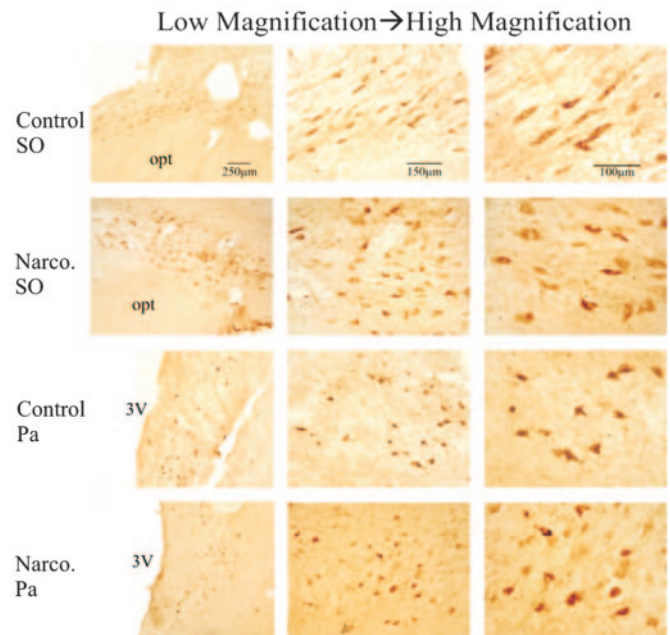


Figure 2. Narp staining in the SO and Pa of narcoleptic and control sections. Left column shows low-power images of the SO and Pa of matched normal and narcoleptic sections. Middle and right columns show increasingly higher-power images of the same area shown in the left column. 3V = third ventricle; opt = optic tract. Scale bars in each column apply to all panels below and within the same column.

DMH, DHA, and PHA of the normal human brain contain Narp, and that Narp staining in these nuclei is decreased by 89% in the narcoleptic tissue. From our data, we conclude that the neuron loss in narcolepsy does not affect Narp-positive neurons in general because we did not find a significant decrease in the number of Narp-positive neurons in the SO or Pa of the narcoleptic hypothalamus. Our results are consistent with data showing that loss of dynorphin mRNA is also specific to the hypocretin neurons.⁹

In summary, these data support the conclusion that the hypocretin neurons are lost in narcolepsy, because this scenario provides the most parsimonious explanation for the loss of Narp, dynorphin and hypocretin in these neurons. It remains to be determined how the loss of Narp might contribute to the symptoms of narcolepsy.

Acknowledgment

Tissue specimens were obtained from the Human Brain and Spinal Fluid Resource Center, VAMC, Los Angeles, CA, which is sponsored by National Institute of Neurologic Disorders and Stroke/NIMH, National Multiple Sclerosis Society, VA Greater Los Angeles Healthcare System, the Narcolepsy Network and Veterans Health Services and Research Administration, Department of Veterans Affairs. The authors thank Desheng Xu for providing Narp antibody. We also thank Robert Nienhuis for technical assistance.

References

1. Thannickal TC, Moore RY, Nienhuis R, et al. Reduced number of hypocretin neurons in human narcolepsy. *Neuron* 2000;27:469–474.

2. Peyron C, Faraco J, Rogers W, et al. A mutation in a case of early onset narcolepsy and a generalized absence of hypocretin peptides in human narcoleptic brains. *Nat Med* 2000;6:991–997.
3. Chou TC, Lee CE, Lu J, et al. Orexin (Hypocretin) neurons contain dynorphin. *J Neurosci* 2001; 21: RC168.
4. Reti IM, Reddy R, Worley PF, Baraban JM. Selective expression of Narp, a secreted neuronal pentraxin, in orexin neurons. *J Neurochem* 2002;82: 1561–1565.
5. Guilleminault C. Narcolepsy syndrome. In: Kryger, MH, Roth T, Dement WC, eds. *Principles and practice of sleep medicine*. 2nd ed. Philadelphia, PA: W.B. Saunders Company; 1994:549–561.
6. Reti IM, Reddy R, Worley PF, Baraban JM. Prominent Narp expression in projection pathways and terminal fields. *J Neurochem* 2002;82:935–944.
7. Mai JK, Assheuer J, Paxinos G. *Atlas of the human brain*. 2nd ed. San Diego, CA: Elsevier Academic Press; 2004.
8. Thannickal TC, Siegel JM, Nienhuis R, Moore RY. Pattern of hypocretin (orexin) soma and axon loss, and gliosis, in human narcolepsy. *Brain Pathol* 2003;13:340–351.
9. Crocker AJ, McCormack SL, Saper CB, Mignot E, Scammell TE. Loss of orexin/dynorphin neurons in human narcolepsy. Presented at: the Society for Neuroscience Meeting; November 12, 2003; Orlando, FL.

Neurology